

## Introduction

With the recent advent of capsule and balloon endoscopy, the way has been opened for endoscopic treatment of the entire small intestine, bringing a new flexibility to the way we approach small intestine diseases. At present, balloon endoscopy is considered an indispensable modality for small bowel examinations.

In the three years since the launch of the Single Balloon Enteroscope, the share of total small intestine observations has reached 50% to 80%, but there are still some cases in which endoscopists encounter difficulty in deep insertion. This gave us the idea of putting together a compilation of deep insertion techniques that we have used to enable insertion in the deeper region of the small intestine. In so doing, we hope to facilitate more accurate diagnoses and better treatment of small intestine diseases using the Single Balloon Enteroscope.

The purpose of this booklet is to provide endoscopists engaged in single balloon endoscopy with a variety of tips for deep insertion. Accordingly, we describe various deep insertion techniques, along with tips on how best to perform them. By classifying the cases and using clear, easy-to-understand illustrations and explanations, this booklet will enable endoscopists from beginners to experts to easily become confident in the most advanced deep insertion techniques. In addition, we also introduced the single-person method (in which a single endoscopist controls both the endoscope and the splinting tube) using the Single Balloon Enteroscope. By enhancing understanding of small intestinal enteroscopic insertion using the Single Balloon Enteroscope, we hope this booklet will contribute to the improvement of diagnosis and treatment of small intestine diseases.

Note: The techniques described in this booklet are based on Japanese cases and practice. You should make any adjustments necessary to suit requirements in your own country.

### Japanese Enteroscope Insertion Technique Study Group (Hospital names in alphabetical order)

Kitasato University East Hospital	Kiyonori Kobayashi	Mitsuhiro Kida
Kyoto Second Red Cross Hospital	Takuji Kawamura	Kenjiro Yasuda
Shiga University of Medical Science Hospital	Tomoyuki Tsujikawa	Yasuharu Saito
Showa University Northern Yokohama Hospital	Kazuo Ohtsuka	Shin-ei Kudo

## Contents

### 1 Deep Insertion Techniques

1-1 Using Carbon Dioxide Gas.....	3
1-2 Using the Distal Attachment.....	4
1-3 Manual Compression.....	4
1-4 Insertion by Forming Large Concentric Circles.....	5
1-5 Tips on Insertion.....	6
1-5-1 When inserting the scope.....	6
1-5-2 When inserting the splinting tube.....	6
1-5-3 When inflating the balloon.....	6
1-6 Prevention of Scope Slip-Back.....	7
1-7 Passage Through a Sharp Curvature.....	8
1-8 Phenomena Proper to Single Balloon Enteroscopy in the Deep Small Intestine.....	9
1-9 Tips for Passing Folds in the Deep Small Intestine.....	10
Example of Total Small Intestinal Observation.....	10

### 2 Antegrade Approach Techniques

2-1 Passage through the Stomach and Duodenum.....	11
2-2 Countermeasures Against Gastric/Upper Small Intestinal Loops.....	11
2-2-1 When a small loop is formed in the stomach and duodenum.....	11
2-2-2 When a small loop is formed in the upper jejunum.....	11

### 3 Retrograde Approach Techniques

3-1 Eliminating a Loop in the Sigmoid Colon.....	12
3-2 Eliminating a Loop in the Transverse Colon.....	12
3-3 Passage through Bauhin's Valve.....	13

### 4 Preventing Accidents

Things to Remember in Accident Prevention.....	14
--	----

### One-Person Method

Advantages of the one-person method.....	15
Explanation of Techniques.....	15

## 1 Deep Insertion Techniques

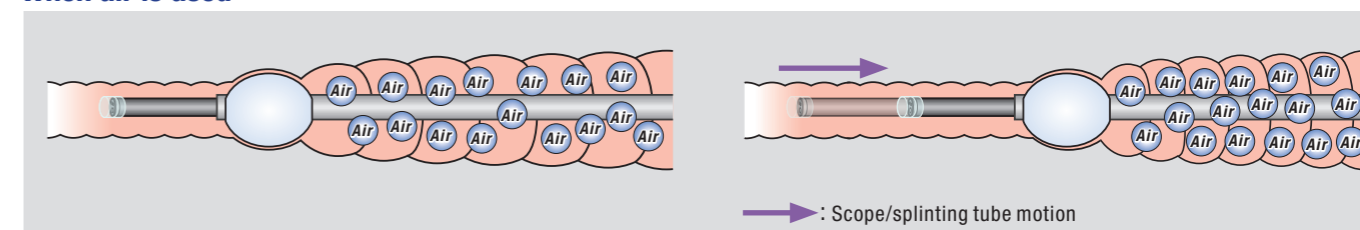
### 1-1 Using Carbon Dioxide Gas

- Using CO<sub>2</sub> gas with high bioabsorbance can make deep insertion easier by preventing excessive stretching of the intestinal tract due to air feed during insertion, and by enabling efficient shortening of the small intestine.

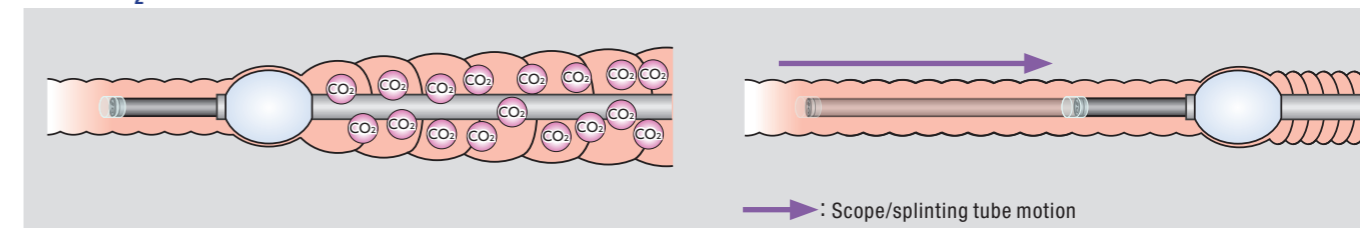


ENDOSCOPIC CO<sub>2</sub> REGULATION UNIT OLYMPUS UCR

#### When air is used



#### When CO<sub>2</sub> is used



### Caution

- Careful judgment on the use of CO<sub>2</sub> is required in cases complicated by serious respiratory diseases such as COPD or chronic cardiac diseases.
- It is recommended that CO<sub>2</sub> and O<sub>2</sub> levels in the blood be monitored during the use of CO<sub>2</sub> gas.

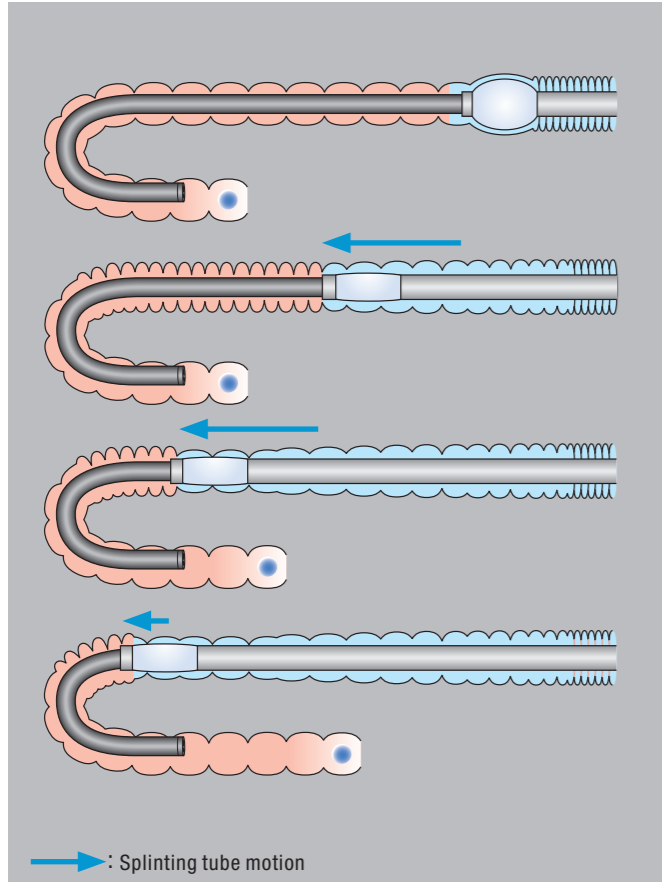
## 1-2 Using the Distal Attachment

- Attaching the distal attachment facilitates insertion by enabling identification of the lumen orientation with a small amount of air feed. On the other hand, however, it makes it impossible to advance or withdraw the scope while leaving the splinting tube inside the body. As the distal attachment cannot be installed once insertion has started, it must be installed in advance if it is to be used.
- When the splinting tube is inserted, the distal attachment holds back the folds, allowing the splinting tube to pass over the folds and facilitating deep insertion.

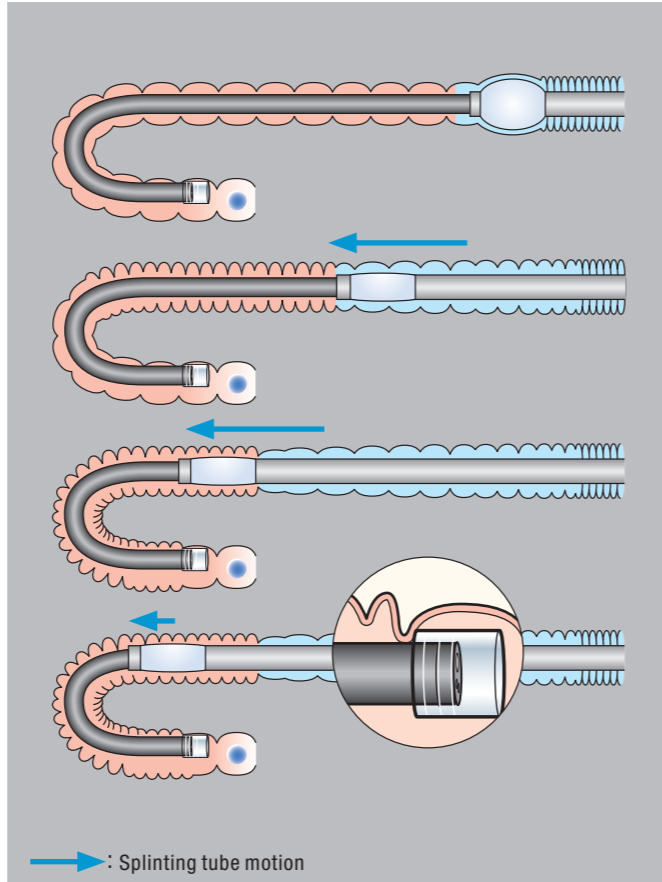


Single-use Distal Attachment  
D-201-10704

### When the distal attachment is not used



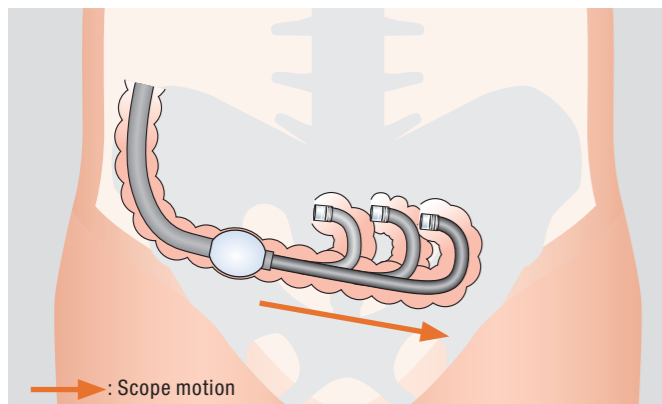
### When the distal attachment is used



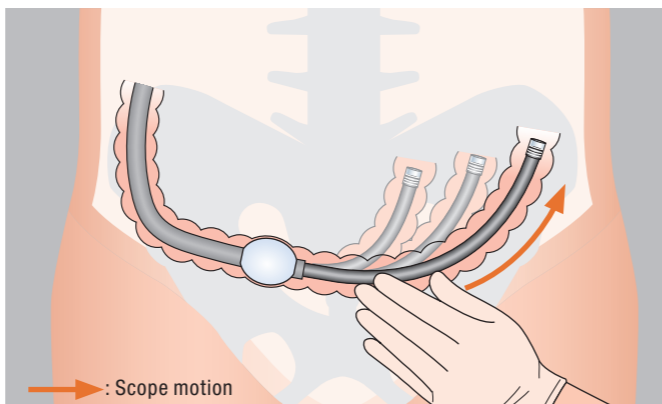
## 1-3 Manual Compression

- When the distal end of the scope forms a crook cane handle shape making deep insertion difficult, manual compression may enable passage by attenuating excessive stretching of the small intestine, as well as by the crook phenomenon.

### Effect of manual compression



The crook hinders transmission of force to the scope's distal end and makes deep insertion impossible.

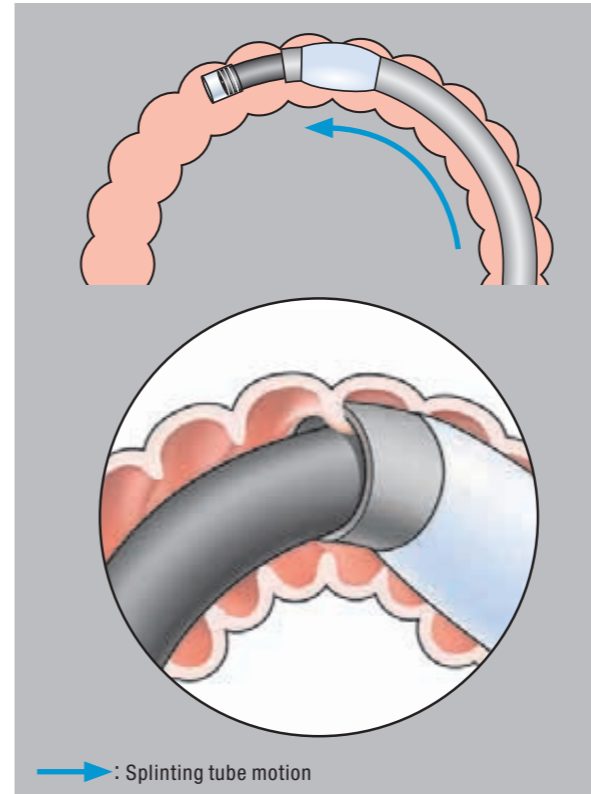


When the crook is corrected by manual compression, the force can be transmitted to the distal end so that deep insertion is possible.

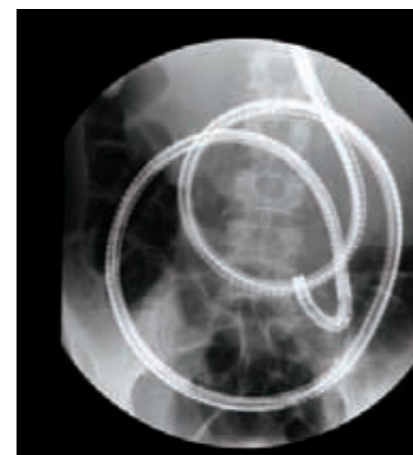
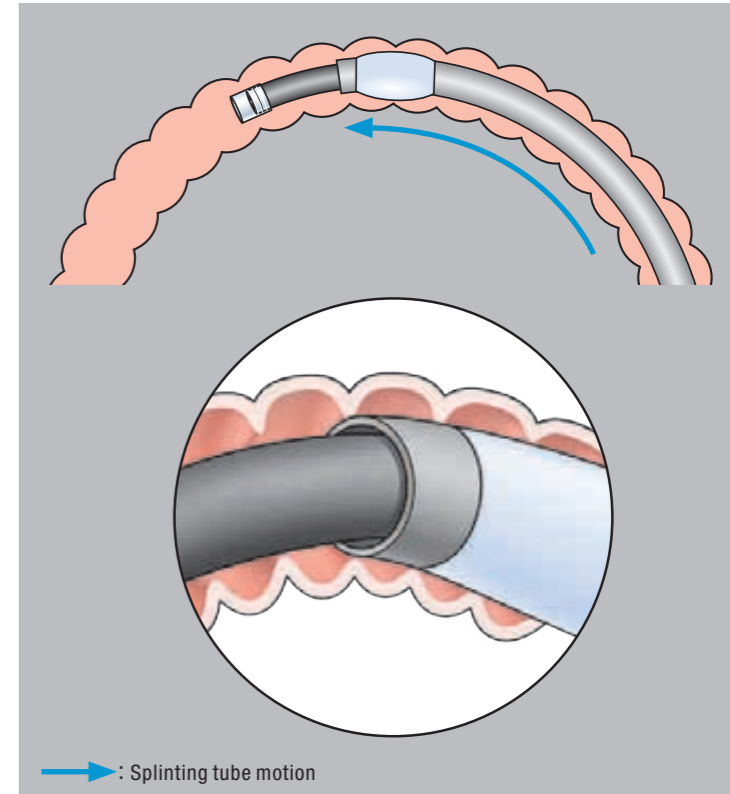
## 1-4 Insertion by Forming Large Concentric Circles

- Insertion by forming large concentric circles facilitates deep insertion.
- The large concentric circles not only eliminate steep curvatures and reduce the drag against splinting tube insertion, but also decreases the risk of mucosa entangling the splinting tube.

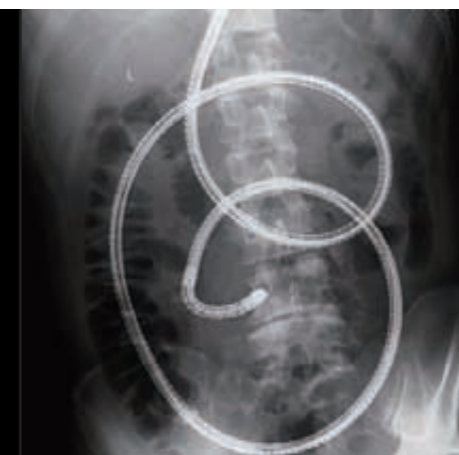### When a small concentric circle is formed



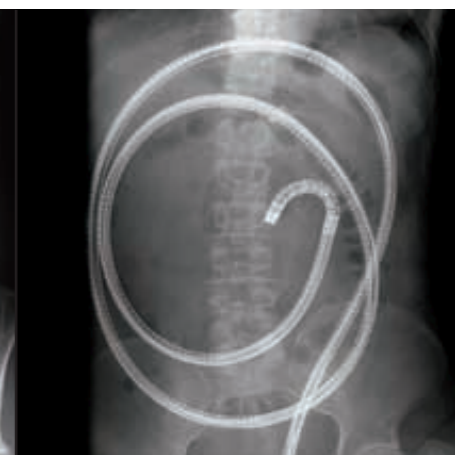### When a large concentric circle is formed



[Antegrade approach]  
(Clockwise)



[Antegrade approach]  
(Counterclockwise)

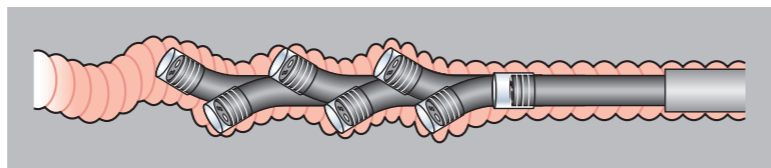


[Retrograde approach]

## 1-5 Tips on Insertion

### 1-5-1 When inserting the scope

- To facilitate deep insertion of the scope, simple pushing is not enough; advance the scope as if pushing through the folds by jiggling the distal end by angulating and squeezing the scope.



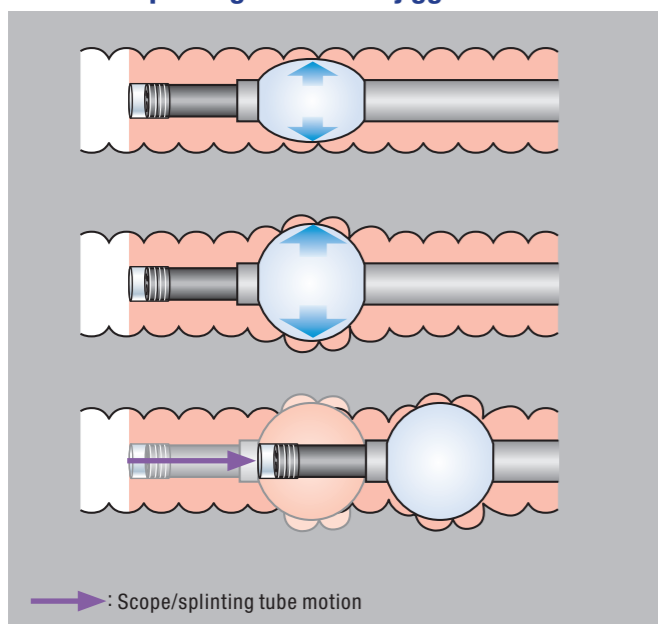
### 1-5-2 When inserting the splinting tube

- Jiggling the scope or splinting tube enables the splinting tube to pass the folds and also reduces the risk of mucosal entanglement.
- Withdraw the scope slightly during splinting tube insertion so that the scope is not pushed in together with the splinting tube.
- To confirm that the splinting tube has passed the folds, the use of fluoroscopy is recommended.

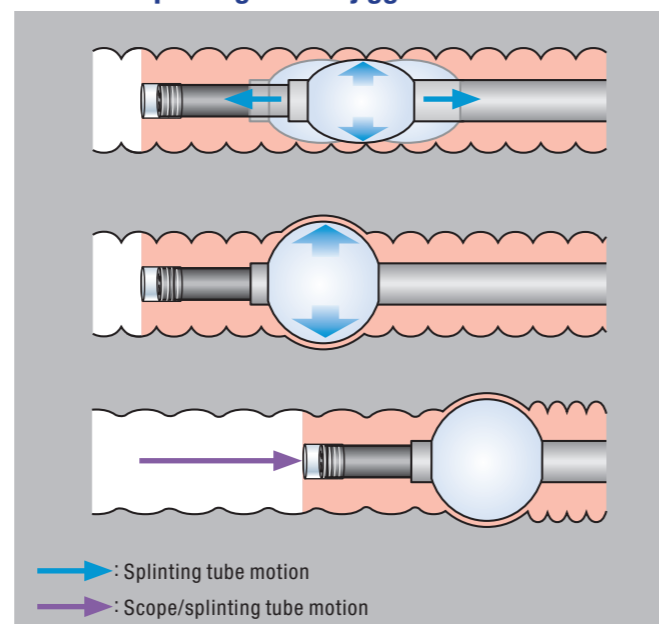
### 1-5-3 When inflating the balloon

- To ensure that the lumen is held firmly by the inflated balloon, it is important not to begin shortening until the OBCU (Olympus Balloon Control Unit) stops blinking, indicating the balloon is fully inflated.
- In the large intestine, which has a wide lumen, inflate the balloon sufficiently to hold the lumen. Otherwise, the balloon may go backward during shortening.
- When the splinting tube is jiggled during balloon inflation, the balloon can be inflated between folds, thereby making possible stable shortening of the intestinal tract.

#### When the splinting tube is not jiggled

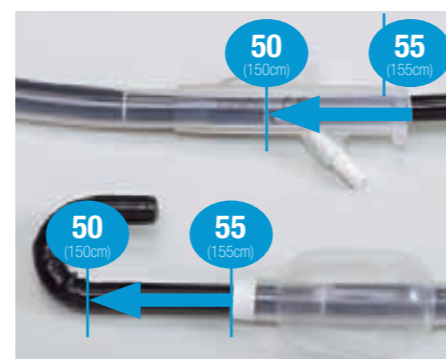


#### When the splinting tube is jiggled



## Technique

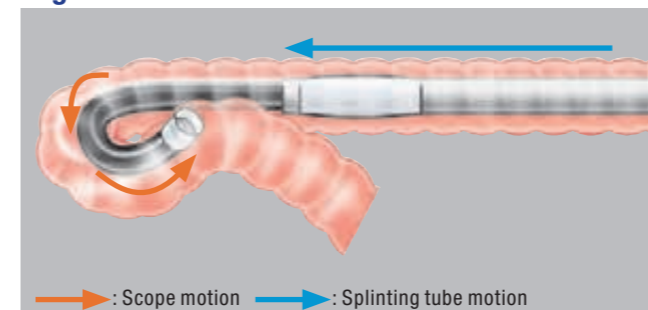
- When the proximal end of the splinting tube is inserted to 55 on the scope's insertion tube scale (i.e. 155 cm from the distal end), the distal end of the splinting tube is advanced to a position slightly before the scope's bending section. In the deep small intestine, the splinting tube should generally be advanced as far as scale 50 (150 cm) or a few centimeters beyond it. Otherwise, the folds may not be passed as the splinting tube is only pushing the intestinal tract.
- After advancement in the deep small intestine, there may be occasions when further advance does not seem possible by single shortening. Even in such a case, repeating the shortening attempt several times may make it possible to pass the obstructing fold and advance to a deeper region.



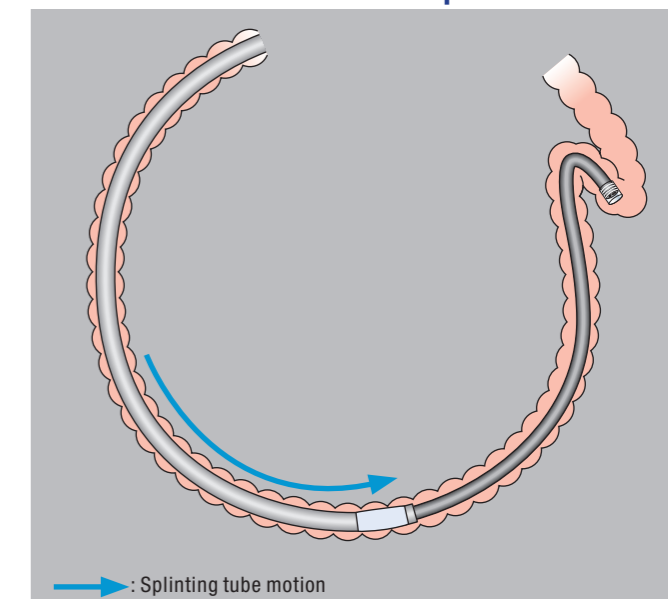
## 1-6 Prevention of Scope Slip-Back

- To prevent the scope from slipping back during the splinting tube insertion, hold the intestinal tract with both up and down angulations.
- If the scope still slips back, the usual means is to hold the intestinal tract with angulation toward the inner direction of the loop. However, scope slip-back can also be prevented by angulating it toward the outer direction of the loop after inserting the scope as far as it will go.
- Using the distal attachment in addition to the above methods is an effective way to prevent slip-back.

### Holding the intestinal tract with both up/down angulations



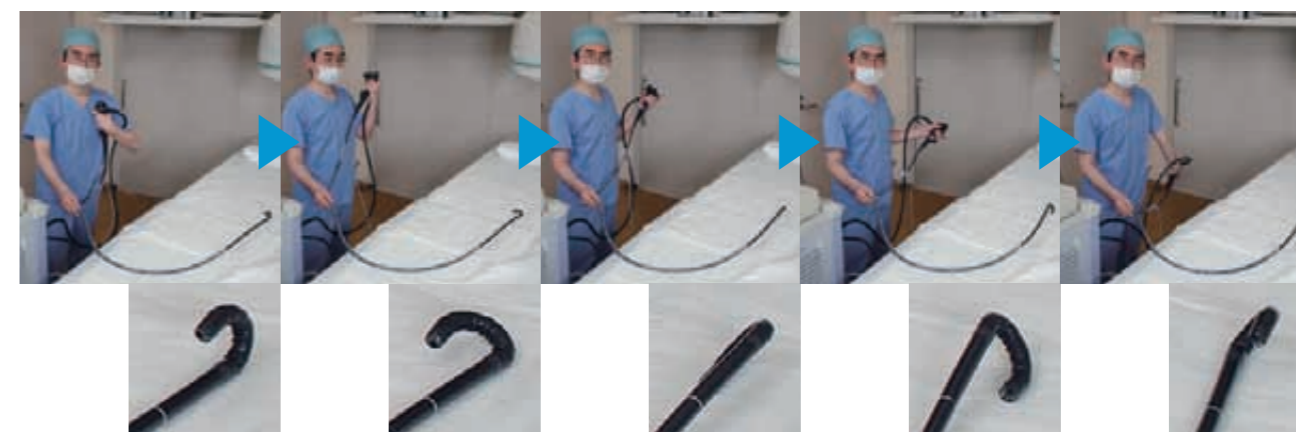
### Holding the intestinal tract with angulation toward the outer direction of loop



## Technique

### Increasing the endoscope's tract holding force

When holding the intestinal tract with angulation toward the outer direction of loop, the tract can be held more strongly by controlling the angulation direction of the scope's distal end arbitrarily by inward and outward rotation of the wrist joint of the hand grasping the scope. However, to prevent injury to the intestinal tract, it is desirable to limit the rotation within the usual working range of the joint.



## Footswitch

- The footswitch makes it possible to inflate and deflate the balloon without removing the hand from the scope or turning the eyes away from the examination image. This makes possible single balloon enteroscopy that is safer, simpler and more efficient.

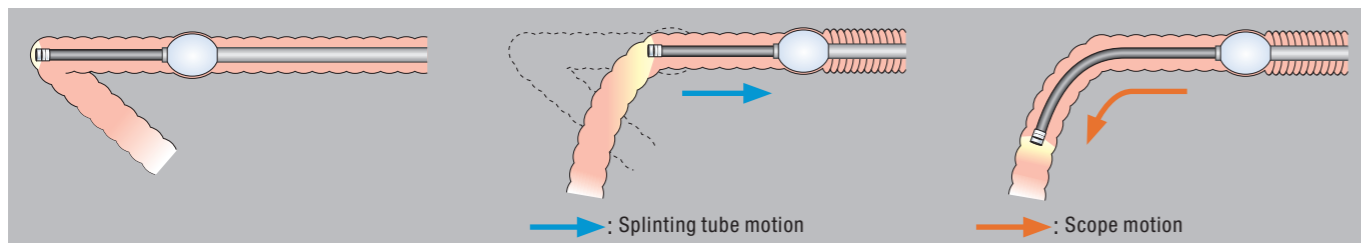


MAJ-1805 (Optional)

## 1-7 Passage Through a Sharp Curvature

### Basic technique

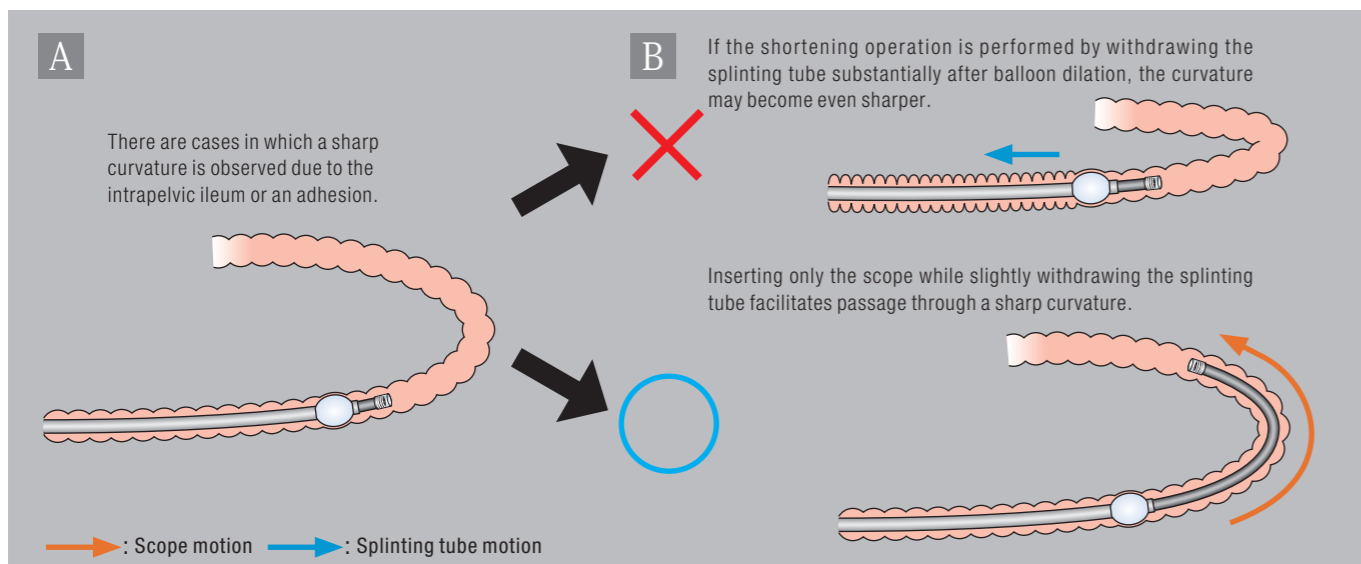
- When the curvature of the small intestine is too sharp and the lumen cannot be found, inflate the balloon before the curvature and pull back the splinting tube slightly. This will attenuate the curvature, securing the view and facilitating insertion of the scope.



### Applied techniques

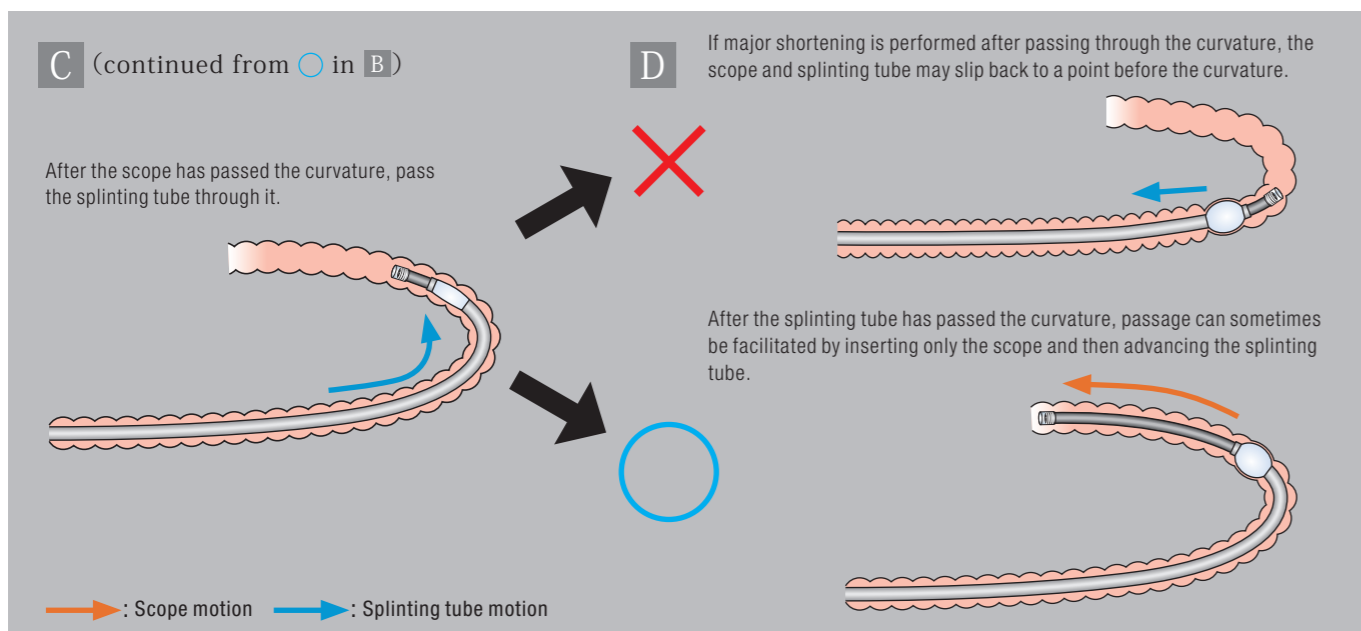
#### Inserting only the scope without significant shortening after balloon dilation

- In a region with a sharp curvature, such as the ileum inside the pelvis, passage of the curvature can sometimes be facilitated by pushing only the scope while slightly withdrawing the splinting tube, instead of pulling back the splinting tube substantially after balloon dilation.
- In a region that is hard to pass due to a sharp curvature produced by adhesion, a similar technique to the above may also be effective.



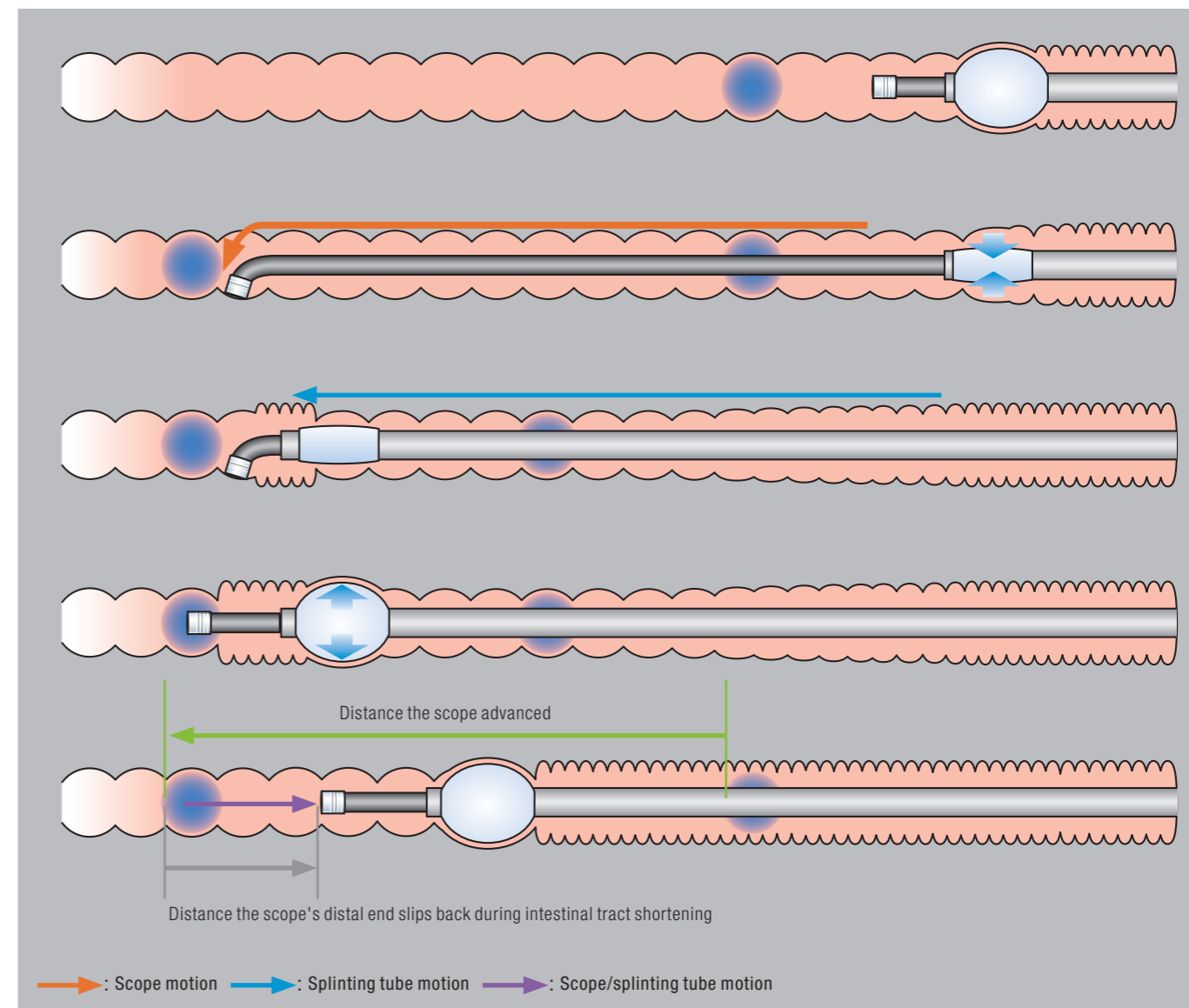
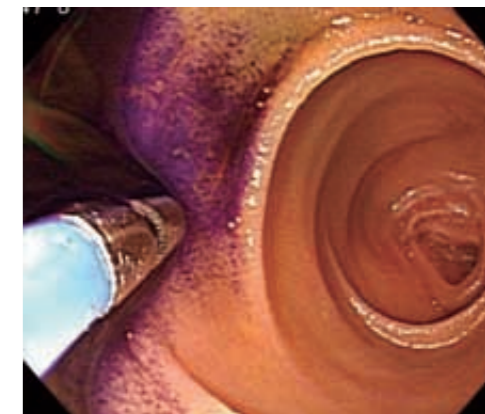
#### Pushing the scope in again without performing significant shortening after passing through a curvature

- After the splinting tube has passed a sharp curvature, the curvature may become sharper if the splinting tube is straightened with a major shortening operation. This can sometimes be prevented by advancing the scope without the shortening operation.



## 1-8 Phenomena Proper to Single Balloon Enteroscopy in the Deep Small Intestine

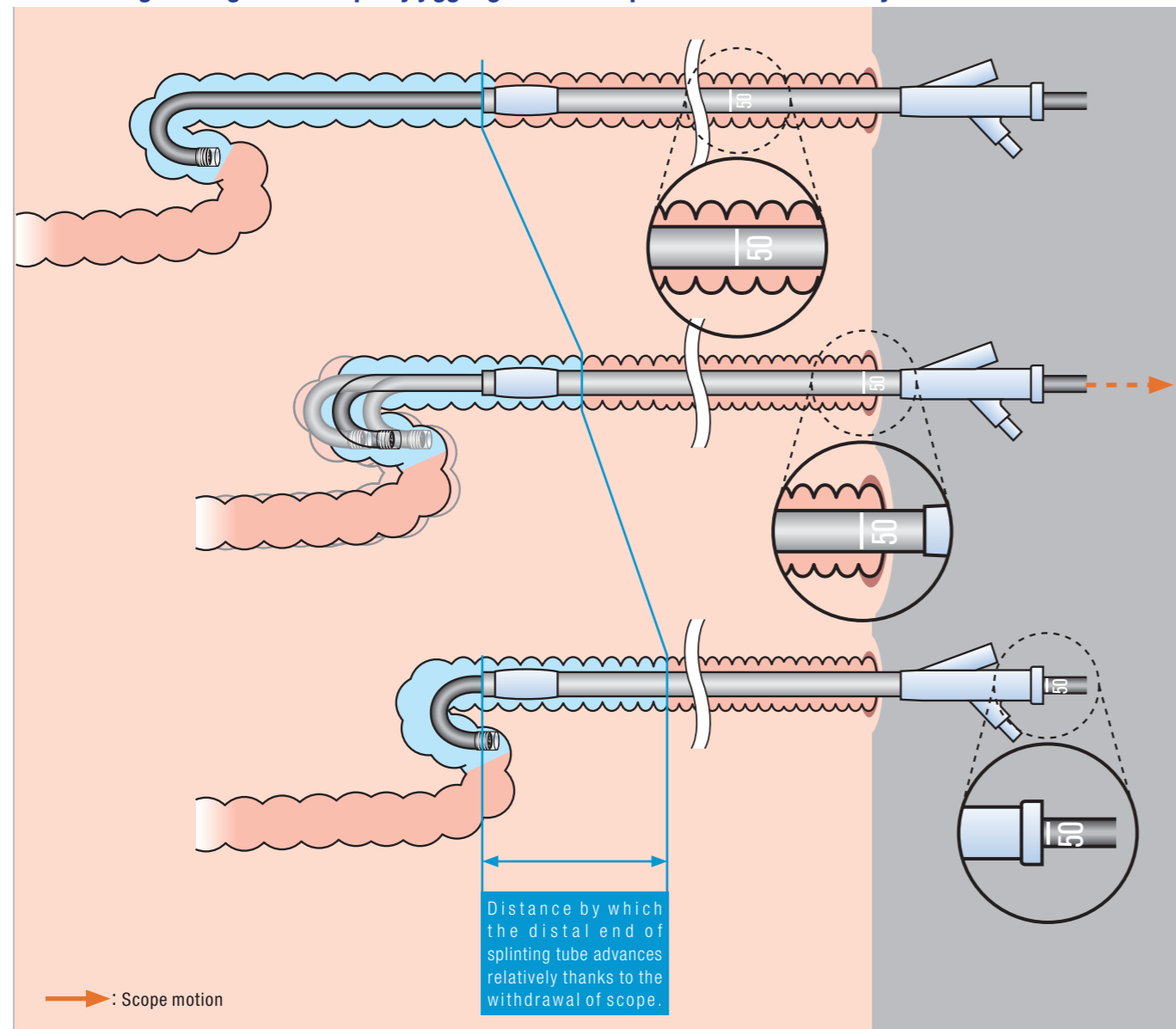
- In single balloon enteroscopy, the scope may look as if it has slipped back when viewed on the monitor because the folds are stretched when they are pushed forward by the inserted splinting tube.
- Even when the scope looks as if it has slipped back in the monitor image, it is actually inserted deeper by an amount equivalent to the folds passed during the splinting tube insertion.
- Marking with crystal violet is useful for confirming insertion.



## 1-9 Tips for Passing Folds in the Deep Small Intestine

- If the distal end of the splinting tube does not reach the scope's bending section (the point where the proximal end of the splinting tube is at the scale 50 position) even when it is inserted as far as it will go in the deepest part of the small intestine, it is sometimes effective to withdraw the scope by jiggling it until the proximal end reaches the scale 50 (150 cm) position while keeping the scope angulated. This may allow the distal end of the splinting tube to advance beyond some folds.

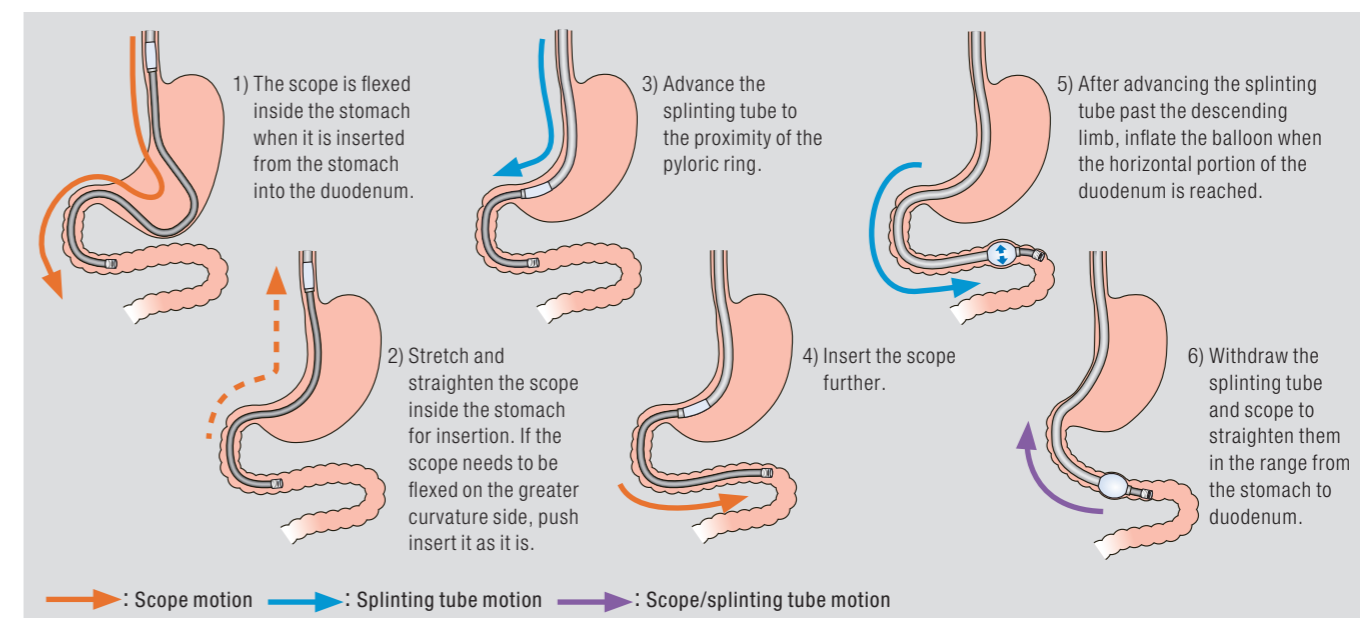
Withdrawing the angulated scope by jiggling it makes it possible to advance beyond some folds.



## 2 Antegrade Approach Techniques

### 2-1 Passage through the Stomach and Duodenum

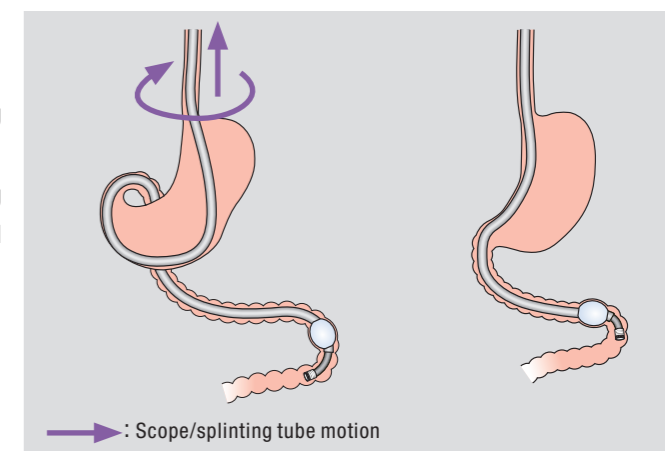
- Stretch and straighten the scope inside the stomach for insertion. If the scope needs to be bent on the greater curvature side of stomach, push insert it as it is.



### 2-2 Countermeasures Against Gastric/Upper Small Intestinal Loops

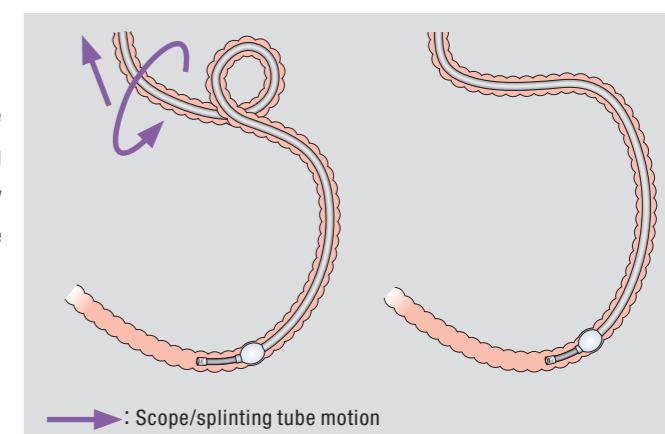
#### 2-2-1 When a small loop is formed in the stomach and duodenum

- During an antegrade approach, a small loop may be formed during insertion from the duodenum into the upper jejunum. In this case, the loop can be eliminated by inflating the balloon after advancing a little, then shortening the duodenum by rotating the scope and splinting tube in the direction that reduces the drag.



#### 2-2-2 When a small loop is formed in the upper jejunum

- In some cases, during insertion, a small loop may form in the upper jejunum. In this case, the loop can be eliminated by inflating the balloon after advancing a little and shortening the jejunum by rotating the scope and splinting tube in the direction reducing the drag.



### Caution

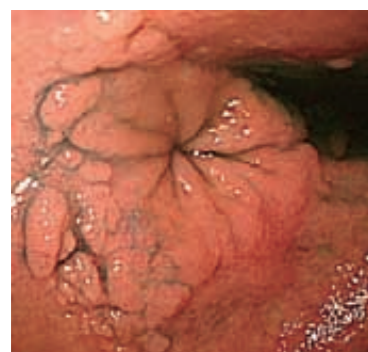
- If any drag is felt during elimination of a loop, it is better not to force the elimination because the drag may be due to fixation or adhesion to an organ.

### Column

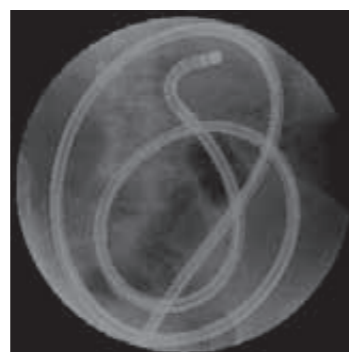
#### Example of Total Small Intestinal Observation

(Dr. Kazuo Ohtsuka, Showa University Northern Yokohama Hospital)

Here is an example of total small intestinal observation by means of retrograde approach. The backside of the pylorus is also observed.



Pylorus viewed from the duodenum. Indigo carmine spraying enables observation of the ectopic gastric mucosa projected onto the bulbus.



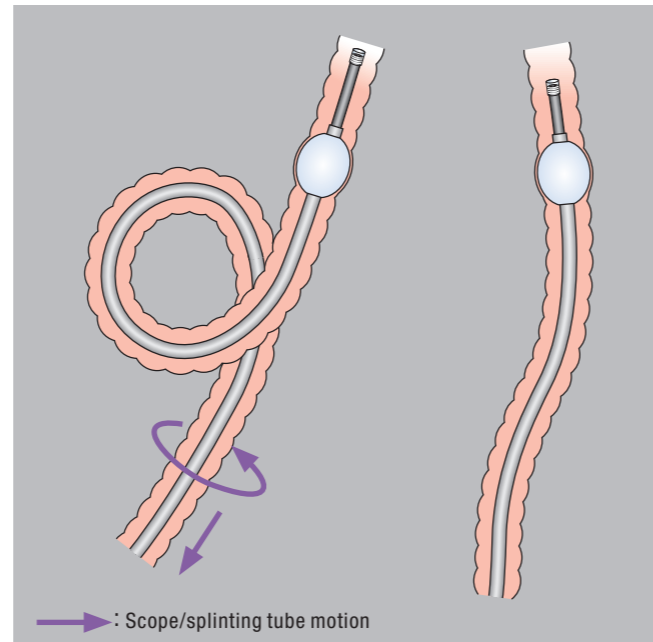
The distal end of the scope inserted in the retrograde approach has reached the duodenum. The small intestine is shortened into a one and half turn.

# 3 Retrograde Approach Techniques

## 3-1 Eliminating a Loop in the Sigmoid Colon

- If a loop is formed in the sigmoid colon, you can eliminate it by holding the intestinal tract with the balloon and withdrawing the scope and splinting tube while rotating them in the direction that reduces the drag.

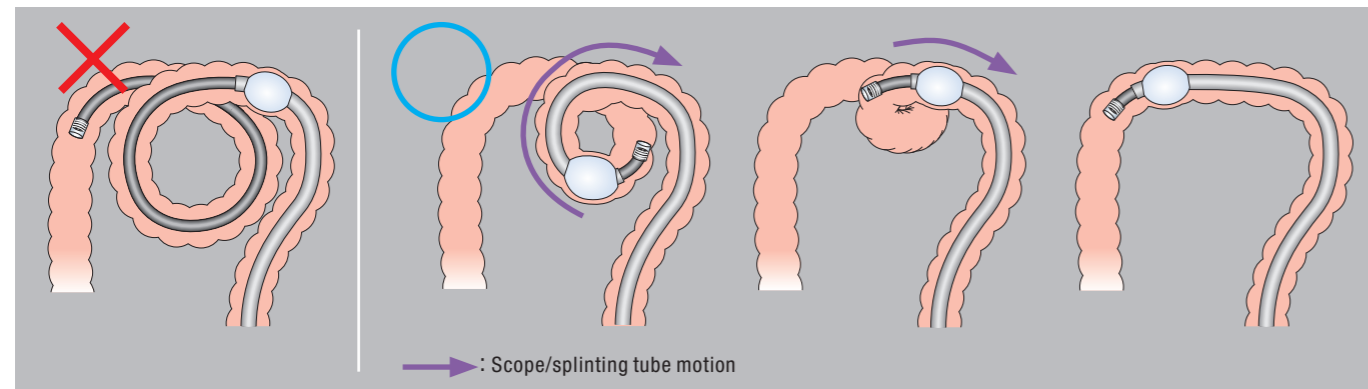
### Eliminating a loop in the sigmoid colon



## 3-2 Eliminating a Loop in the Transverse Colon

- The SIF scope tends to form a loop due to its flexibility. When inserting it into the transverse colon, take care not to form a loop by applying the rotation force in the counterclockwise direction.
- If formation of a loop in the transverse colon cannot be avoided, try to straighten the scope by repeating shortening frequently while continuing insertion.
- If a loop still forms after following the above procedure, insert the scope and splinting tube as far as the ascending colon and then eliminate the loop by rotating them in the direction that reduces the drag.
- Insertion into the deep small intestine will be difficult if the loop in the transverse colon is not eliminated.

### Eliminating loop in transverse colon



A big loop is formed in the transverse colon.

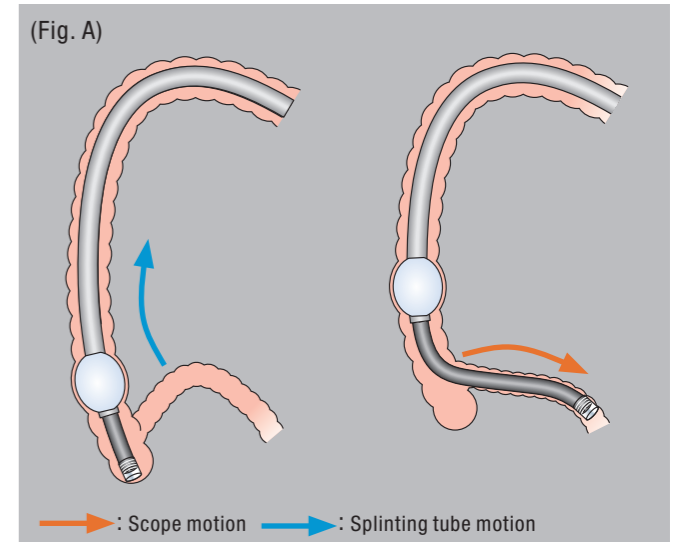
1) If a loop is formed, decrease its size by repeating shortening frequently.

2) Repeat shortening to straighten the scope/splinting tube.

3) Fully straighten them before continuing insertion.

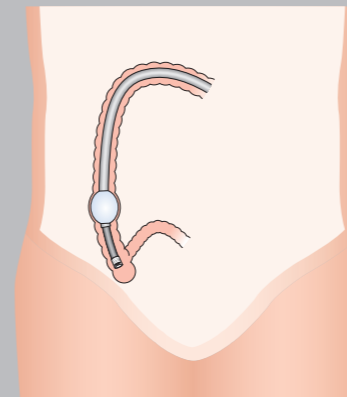
## 3-3 Passage through Bauhin's Valve

- To pass through Bauhin's valve, it is required to inflate the balloon in the ascending colon and performing shortening to reduce the angle of insertion into the ileum in advance. (Fig. A)
- If a large amount of air is present in the ascending colon, it may be stretched, sharpening the angle of insertion into the ileum. To facilitate the passage through Bauhin's valve, it is also important to absorb the air to a degree at which the vision can be secured.
- When passing through Bauhin's valve, insertion can be facilitated by decreasing the angle of insertion into the ileum by means of manual compression or postural change. (Figs. B, C)
- If insertion into the terminal ileum is impossible by any means, try reversing the scope inside the cecum and inserting the U-shaped distal end of the scope into the ileum with push operation. (Fig. D)
- After passing through Bauhin's valve, insert the scope as deep as possible, then advance the splinting tube and, when it has entered the ileum entirely, proceed to balloon inflation and shortening. (Fig. E)
- Shortening inside the terminal ileum tends to cause dropping of the balloon into the colon side. Whether or not the balloon is dropped in the colon can be determined by the time taken by the balloon inflation.

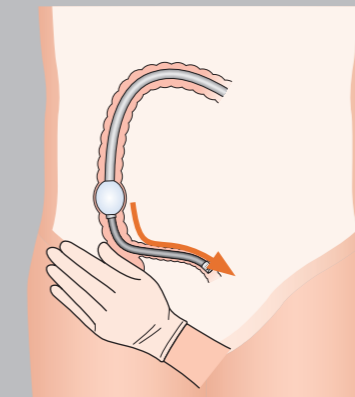


Inflate the balloon of the splinting tube in the ascending colon and withdraw the tube to decrease the ileum insertion angle.

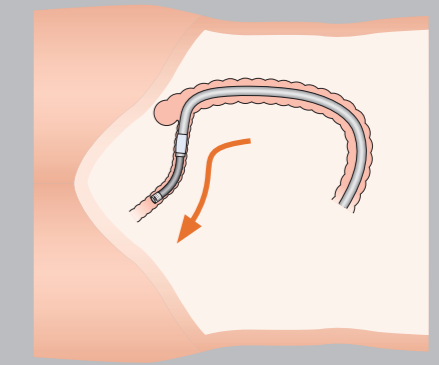
### Before Bauhin's valve passage



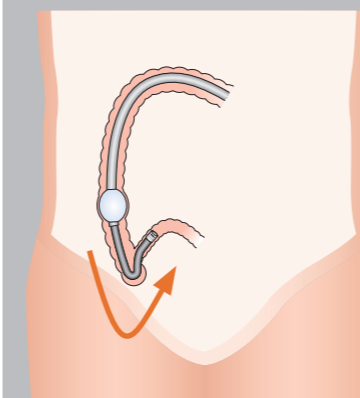
### Manual compression (Fig. B)



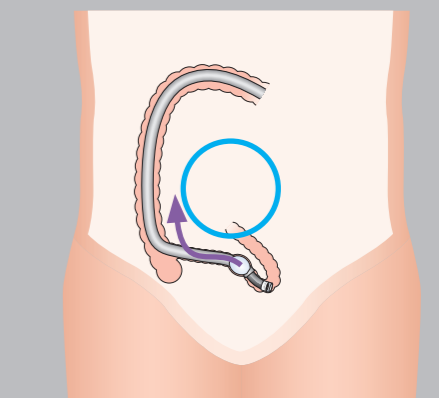
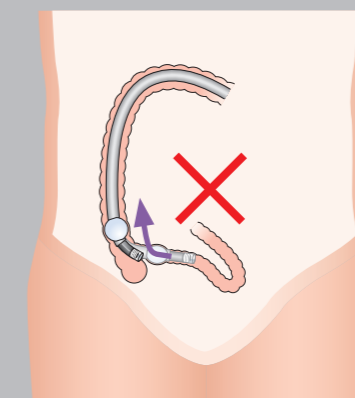
### Postural change (Left arm reclining) (Fig. C)



### Reversal in cecum before insertion into ileum (Fig. D)



### Intestinal tract shortening after insertion into deep ileum (Fig. E)



If the balloon is dilated in the terminal ileum after passing Bauhin's valve and then the intestinal tract is shortened, the balloon tends to drop inside the colon.

After passing Bauhin's valve, insert the scope/splinting tube deep enough before inflating the balloon and shortening the intestinal tract.

Legend: Orange arrow: Scope motion; Purple arrow: Scope/splinting tube motion

## 4 Preventing Accidents

**When deep insertion is difficult, do not try to force insertion. Always keep your patient's comfort and safety in mind.**

### Things to Remember in Accident Prevention

#### Caution when holding the intestinal tract

- Care is required in holding an intestinal tract region in which the intestinal wall is rendered fragile by inflammation or ulcer because it may be perforated if it is held with scope angulation or by using a balloon.

#### Entanglement of intestinal tract during splinting tube insertion

- During splinting tube insertion, there is a risk of injuring the intestinal tract by catching mucosa. To prevent this, squeeze the splinting tube finely to the left and right during insertion. If a drag is felt during insertion, withdraw the tube and retry insertion.
- The risk of mucosal entanglement is especially high in sharp curvatures or in an anastomotic section. Be very cautious in these regions.

#### Insertion and shortening of scope/splinting tube in adhesion cases

- When insertion is difficult due to adhesion, it is often hard to form concentric circles because the mobility of the small intestine is limited. Particularly, when there is a drag during scope or splinting tube insertion or during angulation operation, special care is required not to force insertion or perform shortening as this may lead to perforation.

#### Pancreatitis caused by antegrade approach

- The antegrade approach is accompanied with a risk of acute pancreatitis after examination. Note that insertion for long hours, excessive repeating of shortening and balloon dilation near the duodenal papilla increase the risk of pancreatitis. Also watch for abdominal pains after completing examination.

#### Respiratory depression and aspiration due to sedation

- Following sedation, take care against respiratory depression and pay attention to any changes in vital signs.
- Particularly, the risk of aspiration pneumonia is high in the case of antegrade approach. Absorb the buccal content as required.

#### Deep insertion limit reference

- When inserting the scope deeply, it is important to accurately identify the limit of insertion in order to minimize patient discomfort.
- Specifically, the limit can be determined in the following ways:
  - 1) When images that seem to show the same position are displayed repeatedly: To check if they show the same position, crystal violet marking is effective.
  - 2) When more than one hour has elapsed since the start of insertion: The total procedure time should be less than two hours including observation and treatment.
  - 3) When the intestinal tract has been shortened a few times after the splinting tube has been inserted to the limit.
  - 4) When the patient condition has changed and continuing with insertion seems to be difficult.

## One-Person Method

(Dr. Kazuo Ohtsuka, Showa University Northern Yokohama Hospital)

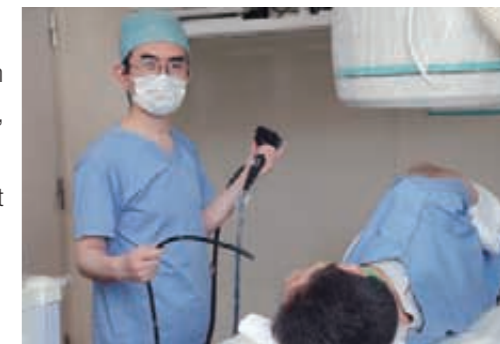### Advantages of the one-person method

- The intention of the endoscopist transmits directly to the scope.
- This method is useful for reducing the risks because the endoscopist can actually feel what is happening with his hand during shortening and while the scope is holding the intestinal tract.
- Eliminating the necessity of an assistant may reduce costs.

### Explanation of Techniques

#### Basic attitude

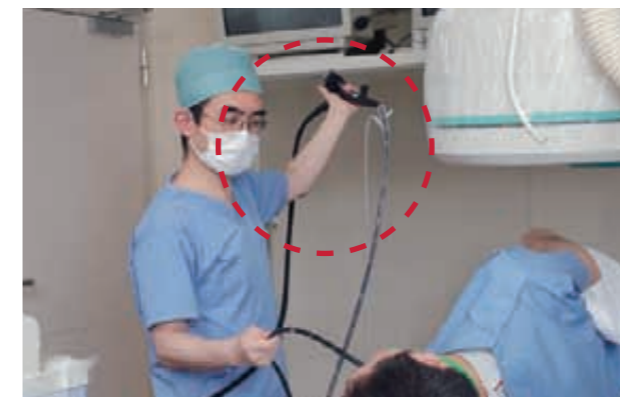- With this method, the endoscopist grasps the scope's grip control section with the left hand, grasps the scope and splinting tube with the right hand, and performs various operations.
- When the balloon controller is controlled with the footswitch, the endoscopist does not have to remove his or her hand from the scope (see page 7).



#### Attitude during insertion

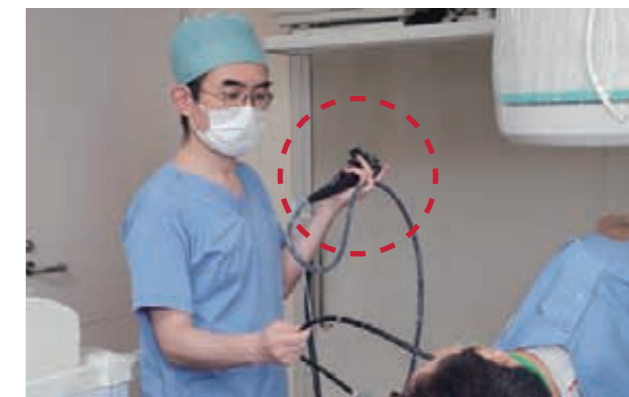##### Grasping the scope at the beginning of antegrade approach (Basic form)

- Extending the left arm grasping the scope control section facilitates handling of the scope.



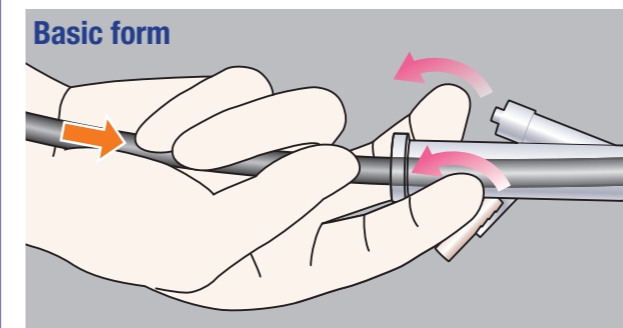
##### Grasping the scope at the beginning of the antegrade approach (Form for a small-build person)

- Grasping the scope outside the body with the little finger of the left hand facilitates handling of the scope.

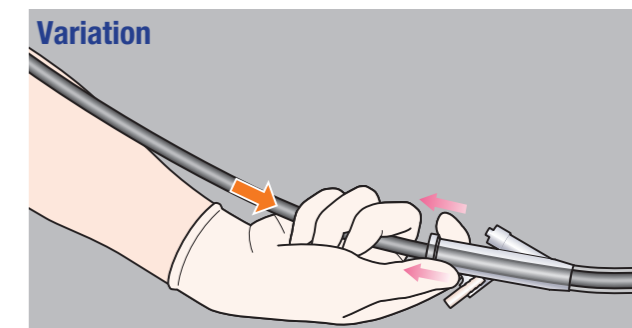


#### How to use the right-hand fingers

- The operation of the right hand during scope insertion includes the basic form in which the index and middle fingers grasp the splinting tube as well as a variation of this, including one in which the thumb and index finger grasp the splinting tube. Use these forms as required during insertion.



Grasp the scope with the thumb, ring finger, little finger and palm, and withdraw the splinting tube by hooking the index and middle fingers on its tab to insert the scope.



Grasp the scope with the middle finger, ring finger, little finger and palm, and withdraw the splinting tube by hooking the thumb and index finger to insert the scope.

# SINGLE BALLOON INSERTION TECHNIQUE FOR REACHING THE DEEP SMALL INTESTINE

Japanese Enteroscope Insertion Technique Study Group